

PUBLISHED BY

INTECH

open science | open minds

World's largest Science,
Technology & Medicine
Open Access book publisher



3,150+
OPEN ACCESS BOOKS



104,000+
INTERNATIONAL
AUTHORS AND EDITORS



109+ MILLION
DOWNLOADS



BOOKS
DELIVERED TO
151 COUNTRIES

AUTHORS AMONG

TOP 1%
MOST CITED SCIENTIST



12.2%
AUTHORS AND EDITORS
FROM TOP 500 UNIVERSITIES



Selection of our books indexed in the
Book Citation Index in Web of Science™
Core Collection (BKCI)

WEB OF SCIENCE™

Chapter from the book *Recent Advances in Scoliosis*

Downloaded from: <http://www.intechopen.com/books/recent-advances-in-scoliosis>

Interested in publishing with InTechOpen?
Contact us at book.department@intechopen.com

Sensorimotor Integration in Adolescent Idiopathic Scoliosis Patients

Jean-Philippe Pialasse, Martin Descarreaux,
Pierre Mercier, Jean Blouin and Martin Simoneau
*Faculté de Médecine, Division de Kinésiologie, Université Laval - Vieillesse, Centre de
Recherche FRSQ du Centre Hospitalier Affilié Universitaire de Québec
Canada*

1. Introduction

Adolescent idiopathic scoliosis (AIS) is a multifactorial disorder with more questions than answers. In past years, research has mainly focused on 5 areas: genetic factors, neurological mechanism dysfunction, hormone/metabolic dysfunction, skeletal growth abnormalities, and biomechanical factors. As adolescents with any known functional or structural disorder in the somatosensory pathway are more susceptible to scoliosis during growth than healthy adolescents, it is possible that subclinical somatosensory impairment may be associated with AIS.

The aim of this chapter is to provide evidence that idiopathic scoliosis (IS) is likely related to neurological mechanism dysfunction. We recognize that no consistent neurological abnormalities have been identified in IS patients, but we nonetheless believe that curvature progression could result from specific neurological impairments. Consequently, we reviewed studies that assessed whether IS patients experience abnormal somatosensory processing. For instance, deficits in the structure and functioning of peripheral systems are of various natures in AIS. Lesions of the posterior column pathway have been implicated as a possible cause of scoliosis. In animal studies, scoliosis has been induced by damaging the posterior column pathway at the dorsal root and in the thoracic cord (Liszka, 1961; Pincott et al., 1984; Pincott & Taffs, 1982). These observations led some researchers to investigate whether IS patients would respond differently than healthy control participants to a mechanical stimulus (Barrack et al., 1988; Byl et al., 1997; Olafsson et al., 2002; Wyatt et al., 1986). No consensus has, however, been reached.

In recent years, several studies have reported sensorimotor impairments in IS patients. We believe that dysfunction of sensorimotor transformation mechanisms during growth results in IS or accelerates curvature progression as motor output could be inefficient, causing asymmetric axial muscle activation. This chapter reviews studies that investigated the potential implication of neurological mechanism dysfunction in IS patients.

1.1 Neurological abnormalities

Magnetic resonance imaging (MRI) and somatosensory evoked potentials (SEPs), 2 among various techniques, have been employed to verify whether scoliosis patients incur neurological abnormalities.

1.1.1 Cranio-cervical MRI

MRI discerns pathological and anatomical variations. These variations sometimes do not imply any visible clinical changes during standard patient examination besides the scoliosis. MRI of the spine and cranio-cervical region can detect aberrations, such as syringomyelia (Inoue et al., 2005; Inoue et al., 2003; Maiocco et al., 1997; Rajasekaran et al., 2010), cerebellar tonsil ectopia (<5 mm) (Cheng et al., 2003; Chu et al., 2007; Inoue et al., 2005; Inoue et al., 2003; Sun et al., 2007) and Arnold Chiari type I malformation (Krieger et al., 2011; Rajasekaran et al., 2010).

Considering that AIS patients are known to be taller than control subjects (Lam et al., 2011; Little et al., 2000) and curvature might be stretching the cord, tonsillar ectopia might be viewed as a consequence of scoliosis. Faster growth of the spine versus the spinal cord during childhood might also be a cause of tonsillar ectopia in some cases (Barson, 1970; Chu et al., 2006). Thus, it would be reasonable to question if ectopia is the result of scoliosis rather than its cause. In Arnold Chiari type I malformation, however, it is acknowledged that suboccipital craniectomy reduces spinal curvature, supporting the above statement (Colombo & Motta, 2011; Krieger et al., 2011).

A prospective study of 200 young Chinese adolescents (age: 10 to 20 years) by Cheng et al. (1999) involved 36 healthy participants, 135 AIS patients with Cobb's angle ranging from 10 to 45° and 29 AIS patients with Cobb's angle >45°. Tonsillar ectopia was detected in 7.3% of AIS patients. Remarkably, 27.6% of AIS patients with Cobb's angle >45° presented tonsillar ectopia. Furthermore, in this cohort, 3.7% of AIS patients had syringomyelia, and 17.2% had Cobb's angle >45°. None of the controls manifested syringomyelia. Tonsillar ectopia incidence in AIS patients was more frequent when syringomyelia was found (66.7% vs. 5.1%). Moreover, Cheng et al. (2003) demonstrated that 17.9% of AIS patients had tonsillar ectopia up to 5 mm below the basion-opisthion line, whereas control cerebellar tonsils were above it (mean=2.8 mm; range 0-10.5 mm).

In India, Rajasekaran et al. (2010) analyzed 177 young patients aged less than 21 years with scoliosis but not those with associated bone destruction, infectious causes, obvious spinal dysraphism or trauma. Patients were divided into 3 groups: congenital scoliosis patients (A), presumed infantile scoliosis, juvenile scoliosis or AIS (B), and other types of scoliosis, including neuromuscular scoliosis (C). MRI revealed intra-spinal abnormalities in group B. In this group, anomalies were observed in 14% of AIS, 27% of juvenile scoliosis, and 25% of infantile scoliosis patients. In group B, all patients with subtle sensorimotor impairments or aberrant abdominal reflexes had intra-spinal anomalies. The most common anomalies were syringomyelia associated with Arnold Chiari malformation and isolated syringomyelia. In addition, scoliosis occurred earlier (mean age=11.4 years) in patients with intra-spinal abnormalities compared to others (mean age=3.2 years). The incidence of abnormalities was also higher when Cobb's angle was greater. The best indicators of intra-spinal irregularities on MRI were: abnormal neurological findings, apical thoracic kyphosis, double curvature and early onset curvature. After excluding those with subtle neurological findings or atypical AIS curvature patterns (apical kyphosis), 4.2% of 71 AIS patients manifested abnormal MRI.

In Japan, Inoue et al. (2003) reported neurological anomalies detected by MRI in 13% of 71 AIS patients with a family history. Similarly, in preoperative MRI screening of 250

individuals, Inoue et al. (2005) found that 18% had neurological abnormalities, and scoliosis started earlier in these individuals. Neurological aberrations were noted in 18% of these 250 individuals after standard neurological examination. Among patients with abnormal neurological signs after standard neurological examination, 57% also had abnormal neurological MRI. These authors reported that the most predictable factors of neural axis malformation were sustained clonus (100% had malformation), asymmetrical superficial abdominal reflexes (71%), hyperreflexia (43%) and diminished sensation (13%).

In Europe, Hausmann et al. (2003) scanned 100 AIS patients before surgical correction. These patients did not feel pain or numbness, and their lower limb strength was normal. In addition, no abnormal neurological sign was observed after standard neurological examination. MRI revealed neurological anomalies in 3% of these patients.

In Turkey, however, Benli et al. (2002) found that preoperative MRI demonstrated neurological abnormalities in 7.1% of 84 AIS patients with absolute flexible thoracic curvatures (i.e., King-Moe type III).

In USA, Shen et al. (1996) reported 4% of abnormal MRI on preoperative screening among 72 AIS patients without any abnormal neurological results. Similarly, preoperative MRI screening of 140 neurologically normal AIS patients disclosed that 2.9% had neurological abnormalities (Winter et al., 1997). Furthermore, Do et al. (2001) reported abnormal findings in 2.1% in AIS patients after preoperative MRI.

Overall, the frequency of abnormal neurological results based on MRI scans varied slightly between studies: from 3% to 18% of AIS patients tested. This range may have been due to the study population. It could also have been related to the absence or presence of subtle neurological deficits and whether the authors classified such cases as AIS. Clinicians might have failed to detect subtle neurological deficits and classified patients as AIS when it was in fact neurological scoliosis.

Also, the definition of neurological abnormalities on MRI is important. When the pathology starts with Arnold Chiari type I malformation, with tonsils 5 mm or more below the basion-opisthion line, some will consider tonsillar ectopia <5 mm as normal and will not report it, whereas others will.

Globally, MRI findings from around the world give good external validity to these observations.

1.1.2 MRI and spinal cord length

Spinal cord length is not significantly different between AIS patients and controls (Chu et al., 2006). However, segmental spinal column lengthening at the thoracic level in AIS patients with severe curvatures gives a significantly reduced cord to vertebral length ratio. There is also no correlation between this ratio and tonsillar ectopia.

1.1.3 MRI of the brain

Other variations might be observed on more precise scrutiny at the brain level. MRI voxel-based morphometry has revealed less attenuation of white matter in the genu of the corpus callosum and left internal capsule in left thoracic AIS girls than in their controls (Shi et al.,

2009). These 2 structures are respectively responsible for interhemispheric communication and corticothalamic projectional fibers. Nevertheless, no difference has been discerned between right-sided thoracic AIS patients and control subjects. Geissele et al. (1991) reported asymmetry of the ventral pons in the area of the cortico-spinal tracts and an enlarged cisterna magna in AIS patients. Moreover, cortical thickness declined significantly with age in almost all cortical lobes except in the temporal lobe of normal subjects (Wang et al., 2012). In contrast, cortical thickness in right thoracic AIS patients did not decrease with age. Furthermore, some significant differences were found between the controls and AIS patients regarding the thickness of areas related to motor and vestibular function.

1.1.4 MRI of the vestibular apparatus

Significant effort has been made recently to develop tools to investigate the 3-D shape of the vestibular apparatus in AIS patients and healthy controls. 3-D measurement of vestibular system morphology in 20 right thoracic AIS patients and 20 healthy girls demonstrated that AIS patients had a smaller distance between centers of the lateral and superior canals and the angle with vertex at the center of the posterior canal in the left side of the vestibular system but not in the right side (Shi et al., 2011).

In addition, structural abnormality with communication between the lymphatic posterior and lateral semicircular canals with a frequency of 55% in 95 AIS patients was described, whereas it was only 15% in 445 participants who underwent MRI and computed tomography (Rousie et al., 1999). This abnormality is associated with the following signs: the absence of rotatory vertigo but frequent instability, transport sickness on head tilt to the side of the anomaly, spatial disorientation in new environments, and nystagmus.

1.1.5 SEPs and AIS

SEPs are frequently measured during corrective surgery. Moreover, SEPs are quantified in patients to determine whether IS is related to central nervous system (CNS) dysfunction. Abnormal SEPs can result from dysfunction at the level of the peripheral nerve, plexus, spinal root, spinal cord, brainstem, thalamocortical projections, or primary somatosensory cortex. Although most studies detected abnormal SEPs in IS patients, some failed to do so. For example, Brinker et al. (1992) and Olafsson et al. (2002) did not find abnormal SEPs in their AIS patients. In contrast, Fernandez-Bermejo et al. (1993) observed asymmetrical latency at the lumbar level in 20 out of 52 AIS patients. Moreover, Machida et al. (1994) noted abnormal SEP latency in chickens with experimentally-induced scoliosis and AIS patients. In this study, AIS patients with a single curvature had longer N37 latency when the tibial nerve was stimulated ipsilateral to the concave rather than the convex side. Moreover, N37 latency was delayed on both sides in AIS patients with double curvature. It is noteworthy that these authors observed abnormal SEP latency in 97% of their AIS patients (Machida et al., 1994).

A preoperative study revealed that only 3 out of 72 AIS patients (i.e., 4.2%) had abnormal SEPs on normal standard neurological examination (Shen et al., 1996). Two of these patients had asymmetrical P37 latency despite normal MRI. Other AIS patients presented subcortical responses after left tibial nerve stimulation but no cortical responses, indicating dysfunction of the ascending sensory pathways at the thalamocortical or cortical level. However, MRI pointed to Arnold Chiari type I malformation in these patients.

Hausmann et al. (2003) reported that 68% of 100 AIS patients with Cobb's angle ranging from 43° to 96° had abnormal SEPs before surgery, with 56% having body height corrected prolonged latency increased and 12% with pathological right and left differences.

Another study examined 147 AIS patients and 31 controls to determine whether the former have abnormal SEPs compared to the latter (Cheng et al., 1998). None of the AIS patients and controls had clinically-detectable neurological deficits. In this study, the authors analyzed P37 and N45 latencies and inter-side latency differences. The results revealed that inter-side latency differences in AIS patients were 1.1 (± 1.6) ms and 1.2 (± 1.6) ms for P37 and N45, respectively. In contrast, in the controls, inter-side latency was only 0.2 (± 0.3) ms for P37 and N45. Overall, these findings demonstrated that inter-side latency differences were significantly larger in scoliosis patients, indicating asymmetric conduction velocity of electrical signals in somatosensory pathways compared to the controls. Absolute latencies and inter-side differences in latencies were abnormal in 11.6% of AIS patients. Consequently, this observation suggests that AIS could be divided into 2 subgroups, one with disorders of the somatosensory pathways, and the other with normal somatosensory pathways. In a subsequent prospective study, Cheng et al. (1999) attempted to correlate clinical scoliosis severity with structural abnormalities on MRI and SEP-detected functional disorders in the hind brain and spinal cord. In this investigation, 135 AIS patients and 36 healthy subjects consented to MRI and SEP examination. Abnormal SEPs were observed in 24 (14.6%) AIS patients. Approximately 12% and 28% of AIS patients with moderate and severe spine curvature had abnormal SEPs. The higher prevalence of abnormal somatosensory function in patients with severe curvature was significant. The authors calculated a significant correlation between tonsillar ectopia and abnormal SEPs ($r=0.672$); most of the patients (i.e., 66.7%) with tonsillar ectopia had abnormal SEPs. In contrast, in 160 patients without tonsillar ectopia, only 10% had abnormal SEPs. None of the controls had tonsillar ectopia or abnormal SEPs. In a subsequent study, the same research group calculated the spinal cord length to vertebral column length ratio, evaluated the position of the cerebellar tonsils, and correlated these data with SEPs (Chu et al., 2006). The results revealed that 43% of AIS patients (i.e., 6 of 14 patients) with Cobb's angle $>40^\circ$ and 14% of AIS patients (i.e., 2 of 14 patients) with Cobb's angle $<40^\circ$ had abnormal SEPs. Remarkably, there was no significant difference between cord to vertebral ratio and tonsillar level between patients with normal and abnormal SEPs. Finally, all controls had normal SEPs. In a parallel study, the same research group observed that 14.3% of 105 AIS patients with Cobb's angle ranging from 10° to 35° had abnormal SEPs (Guo et al., 2006). The novelty of this research was that it investigated if previously-reported balance control impairment in AIS patients was associated with scoliosis or abnormal somatosensory function. A significant difference in standing balance control was found between AIS patients with abnormal SEPs and the controls when relying on somatosensory input. Two years later, the same research group conducted another study in which SEPs were examined in 35 AIS patients with Cobb's angle $<40^\circ$, 26 AIS patients with Cobb's angle $>40^\circ$, and 36 controls. Overall, 23.0% of all AIS patients had abnormal SEPs; 9% and 42% had moderate and severe curvatures, respectively. Again, all controls had normal SEPs (Chu et al., 2008). It seems evident that some AIS patients have abnormal SEPs.

This review found that approximately 14 to 68% of AIS patients had afferent conduction abnormalities, whereas Machida et al. (1994) noted that 97% of AIS patients had aberrant SEPs.

1.2 Motor and balance control impairment

Herman et al. (1985) reported that AIS patients exhibited perceptual impairments, sensorimotor adaptation deficits and motor learning and balance control shortfalls. According to them, these deficits are the signature of disorders at higher integrative levels of the CNS. Furthermore, ocular and balance stability impairments in AIS patients designate the brainstem as a common target as it mediates sensory information for both the postural and oculomotor systems.

Transcranial magnetic stimulation explores motor responses as well as cortical inhibition and facilitation. A recent study showed no difference in motor responses to a single stimulation between AIS patients, congenital scoliosis patients and control individuals. It suggests that the motor circuit itself is not different. However, significant right/left asymmetry in cortical excitability was characterized by short-latency cortico-cortical inhibition and intra-cortical facilitation after paired pulse stimulation of the motor cortex (Domenech et al., 2010), reflecting a relative decrease in intra-cortical inhibition circuits of the motor cortex. Such dysregulation with hemispheric asymmetry in motor activity modulation of spinal posture at the intra-cortical level could cause or enhance the scoliotic deformity. Furthermore, the fact that congenital scoliosis patients have the same response as the controls tends to reinforce the view that the response is not a consequence of the deformation.

Spinal reflexes have been investigated during surgery (Maguire et al., 1993). Long-latency reflex activity has been observed in all AIS patients but not in non-AIS patients. The reflex, the result of polysynaptic spinal cord processing, might represent segmental disinhibition. It is unclear if this is the consequence of a segmental or supra-segmental abnormality, but the reflex is absent in normal subjects. Moreover, its absence in non-AIS patients confirms that it is not the result of the deformity itself.

AIS patients manifest greater balance instability than controls when sensory information is manipulated, and they have abnormal postural perception (Byl & Gray, 1993; Herman et al., 1985; Sahlstrand et al., 1978). However, without sensory manipulation, some studies did not observe greater body sway in AIS patients compared to their controls (Byl & Gray, 1993; Herman et al., 1985). Moreover, the assessment of balance control either with eyes open or closed showed larger Center of Pressure (CP) area and larger medio-lateral (ML) body sway in AIS patients with larger Cobb's angle (15° - 25°) compared to AIS patients with smaller Cobb's angle (5° - 14°) (Haumont et al., 2011).

Other studies have observed larger body sway area and CP displacement in AIS patients compared to their controls (Beaulieu et al., 2009; Byl et al., 1997). In the study by Beaulieu et al., AIS patients were divided into a pre-brace group (brace prescribed but not yet worn) and an observation group. This classification was adopted because more clinical criteria than Cobb's angle alone were considered (i.e., age, Risser sign, Cobb's angle, gibbosity and history of scoliosis in the immediate family). It turned out that pre-brace AIS patients had larger Cobb's angle than the observation group. The results revealed that pre-brace AIS patients had a smaller mean peak and larger mean distance than the controls (Beaulieu et al., 2009). Larger body sway area and CP displacement were noted in the observation group compared to the controls. The results suggest that the observation group could represent an intermediate sensorimotor condition between the control and the pre-brace AIS groups. The

severity of scoliosis in pre-brace girls might be related to an increase in sensorimotor integration disorder.

Recently, Lao et al. (2008) reported dynamic balance control impairment during gait. These authors recorded significant differences between the right and left limbs for peak vertical force and antero-posterior (AP) maximal propulsive ground reaction force in AIS patients with abnormal SEPs. Besides, the data were more significant for the right limb compared to the left limb. Right and left limb asymmetries were also found in AIS patients with abnormal SEPs for minimum hip joint moment and maximum knee and ankle joint moments. The novelty of these results was the finding of greater gait impairments in AIS patients with abnormal SEPs. Similarly, they demonstrated that AIS patients with abnormal SEPs have poorer static balance control when they have to rely on somatosensory inputs (Guo et al., 2006).

2. Is AIS related to sensorimotor integration impairment?

Lesions of the posterior column pathway have been suggested to be a possible contributing factor in scoliosis. In animal studies, scoliosis has been induced by damaging the posterior column pathway at the dorsal root and in the thoracic cord (Liszka, 1961; Pincott & Taffs, 1982). This indicates that sensory problems could cause IS and it led some researchers to investigate whether IS patients would respond differently than age-matched controls to vibratory stimuli (Barrack et al., 1988; Byl et al., 1997; Olafsson et al., 2002; Wyatt et al., 1986). These studies were not, however, in agreement. For example, Wyatt et al. (1986) and Barrack et al. (1988) found that AIS had a lower proprioceptive threshold (more sensitive) whereas McInnes et al. (1991) reported that AIS patients had a significantly higher vibratory threshold (less sensitive) than control subjects. It is noteworthy that the proprioceptive system threshold can be evaluated via responses to vibration stimulation; they do not determine the capability of the brain to transform sensory perception into appropriate motor responses.

3. Integration and responses in sensory deprivation of visual and proprioceptive information

One way to assess the ability of the brain to transform available sensory inputs into appropriate motor commands is to manipulate sensory information and quantify its effect on balance control. Indeed, sensory deprivation in AIS patients exacerbates body sway oscillations (Sahlstrand et al., 1978; Simoneau et al., 2006a; Simoneau et al., 2006b). These studies clearly demonstrate sensorimotor integration impairments in AIS.

3.1 Sensory deprivation and balance control in AIS patients

More than 3 decades ago, Sahlstrand et al. (1978) explored the effect of removed vision and/or attenuated plantar sole mechanoreceptor information (i.e., participants stood on a compliant support base) on balance control in AIS patients. Their study revealed that attenuating sensory information originating from mechanoreceptors of the soles and/or occluding visual information increased the sway area of AIS patients to a greater extent than that of the controls. One limitation of this study is that standing on a compliant surface may affect balance stability itself (unstable support base). Therefore, standing on an unstable surface may exacerbate AIS patients' balance control problem.

To assess balance control, researchers usually quantify the kinematics of the CP as it depicts overall CP behaviour (e.g., total sway area, CP range, CP root mean square (RMS) velocity, etc.). This type of analysis, however, does not evaluate balance control commands. Consequently, Baratto et al. (2002) proposed a new approach to analyze the causes of overall CP behaviour. For instance, sway density curve analysis permits to determine whether body sway kinematics result from greater or more variable balance control commands.

A study in our laboratory (Simoneau et al., 2006b) expanded on the work of Sahlstrand et al. (1978) by deploying a different technique to manipulate lower limb proprioception: we applied tendon vibration to mask ankle proprioception. Furthermore, we assessed the underlying cause of greater body sway oscillations in AIS by quantifying the sway density curve. Eight scoliosis patients (7 females and 1 male; mean age: 16.4 years, Cobb's angle: $45.6^{\circ} \pm 7.5^{\circ}$) and 10 healthy young girls (average age 16.5 years) were tested. In this experiment, the study subjects stood barefoot on the force platform with their feet 10 cm apart and arms alongside their body. They maintained an upright standing posture while fixating on a small target in their central vision. They were subjected to 4 different experimental conditions. Three sensory deprivation conditions were created by manipulating sensory information: 1. no vision, 2. perturbed proprioception/vision and 3. perturbed proprioception/no vision. No sensory manipulation was the control condition.

By controlling the availability of sensory information and quantifying the outcome, i.e., CP range and CP RMS velocity, we could objectively ascertain the role of visual information and/or ankle proprioception on balance control. Overall, the results revealed that the CP range and CP RMS velocity of AIS patients were larger than those of the controls when ankle proprioception was attenuated. This was seen whether vision was available or not. An important observation, it suggests that despite the availability of vision, AIS patients rely much more on ankle proprioception to scale the amplitude of their balance control commands than control participants. It could be hypothesized that CP kinematics (greater CP range and CP RMS velocity) and greater balance control commands in AIS patients, compared to control participants, result from difficulty in reweighting gains of the vestibular system and the remaining sensory inputs after ankle proprioception alteration whether vision is available or not. Furthermore, sway density curve analysis demonstrated that these observations could be explained by amplitude rather than balance control command variation.

Overall, our interpretation of the results is that IS interferes with the neural mechanism that weighs the remaining sensory inputs. Such a mechanism is necessary to map these inputs into appropriate balance control commands. The remaining sensory information should come from the soles of the feet, the joints above the ankles, and the vestibular apparatus. Finally, we concluded that, compared to the controls, AIS patients rely much more on ankle proprioception to control the amplitude of balance control commands.

3.2 Sensory reweighting and balance control in AIS patients

A key finding of human balance control is that the integration of sensory information appears to be dynamically regulated to adapt to changing environmental conditions and the availability of sensory information; this process is called sensory reweighting. In another study conducted in our laboratory, we assessed the ability of AIS patients to perform sensory reweighting (Simoneau et al., 2006a). The framework to determine the ability of the

brain to reweigh sensory information consists of monitoring balance stability during transient sensory perturbation, for example, when vision is removed and then becomes available again. In this circumstance, a decrease in balance stability (e.g., a sudden increase in body sway) could result from difficulties in dynamically reweighting sensory information when it is made available after a period of deprivation.

In this experiment, 8 scoliosis patients (7 females and 1 male; mean age: 16.3 ± 2.3 years, Cobb's angle: $45.6^\circ \pm 7.5^\circ$) and 9 healthy adolescent girls (average age 16.5 ± 1.7 years) were tested.

Participants stood barefoot on a force platform with their feet 10 cm apart and their arms alongside their body. They maintained an upright posture while fixating on a small target in central vision. All subjects performed 6 trials in each experimental condition. Each trial lasted 30 s and was divided into 2 epochs of 15 s. During the first interval, sensory information (vision and/or proprioception) was occluded (vision) or masked (ankle proprioception, tendon vibration applied at the ankles). In the second epoch, sensory information (vision and/or ankle proprioception) was returned; participants opened their eyes and/or tendon vibrations were stopped. This procedure aimed to assess the immediate effect of change in the availability of sensory inputs on balance control. The different sensory transition conditions were: 1. reintegration of vision under normal proprioception (RV-P), i.e., no vision/proprioception to vision/proprioception, 2. reintegration of proprioception under vision (RP-V), i.e., perturbed proprioception/vision (PP-V) to RP-V, and 3. reintegration of proprioception without vision (RP-NV), i.e., perturbed proprioception/no vision (PP-NV) to RP-NV. The ability of participants to control their balance was also evaluated in trials without any sensory manipulation for 30 s (control condition). The experimental conditions were randomized within the experimental session and across participants.

ML and AP velocities of the CP were calculated according to the finite difference technique. To characterize balance control, we computed CP RMS velocity along the ML and AP axes. This parameter measures the variability of CP velocity. To study the mechanisms causing more variable CP velocity during sensory transition, we analyzed the sway density curve (Baratto et al., (2002). Peaks of the sway density curve correspond to time instants in which the CP and presumably associated balance motor commands are relatively stable. Mean peak represents the time spent by CP inside the 3-mm radius circle centered at the time of peak on the sway density curve. Consequently, peak amplitude estimates the variability of balance control commands.

In the control condition, for both axes, compared to the controls, AIS patients showed greater CP RMS velocity and it was larger for the AP than for the ML axis. Sway density curve analysis revealed that in the absence of sensory manipulation, AIS patients' balance control commands were greater and more variable than those of the controls for mean distance and mean peak.

Balance stability analysis after the reintegration of vision showed that AIS patients had greater CP RMS velocity than the controls along both axes (Fig. 1, upper panel). Analysis of the sway density curve and time spent within the zones of stability (Fig. 1, lower panel) revealed that the balance control commands of AIS patients were much more variable than those of the controls as they spent less time within the 3-mm radius circle (lower mean peaks).

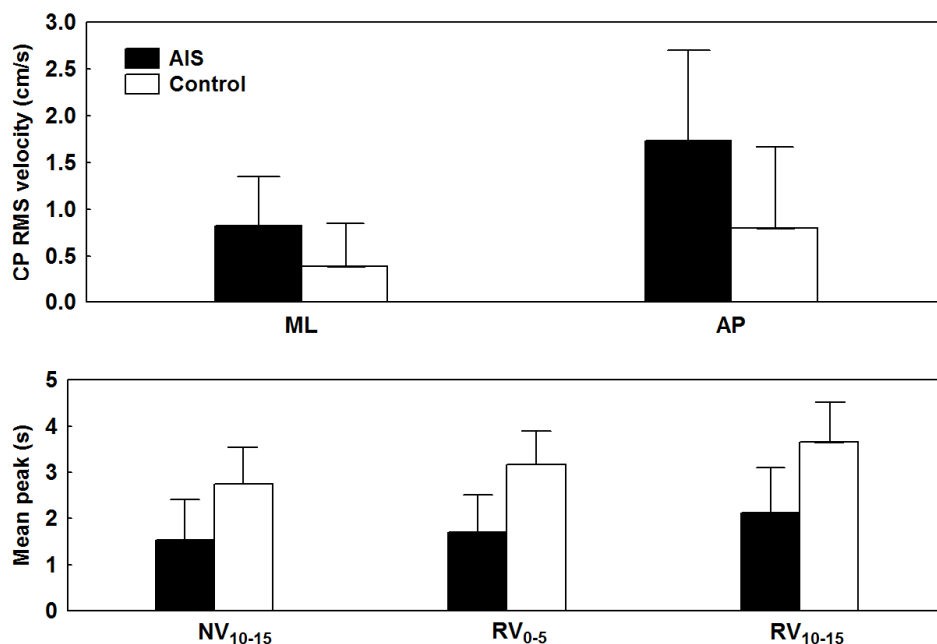


Fig. 1. Balance control performance during reintegration of vision. Upper panel – Group means of CP RMS velocity along the ML and AP axes for the proprioception/no vision to proprioception/reintegration vision condition. The lower panel illustrates Group by Epoch interaction for time spent within the zones of stability (mean peak) for the last 5-s epoch of the proprioception/no vision interval (NV₁₀₋₁₅) and the first 5-s epoch (RV₀₋₅) and last 5-s epoch (RV₁₀₋₁₅) of the proprioception/vision reintegration intervals. In both panels, the error bars indicate 95% confidence intervals. Cited from Simoneau et al. 2006a BMC Neuroscience under Creative Commons licence.

Balance stability analysis after reintegration of proprioception when vision was available revealed that CP RMS velocity increased in AIS patients but not in the controls (Fig. 2, upper panel: PP-V₁₀₋₁₅ to RP-V₀₋₅). Across time (RP-V₀₋₅ versus RP-V₁₀₋₁₅), however, AIS patients improved their balance as CP RMS velocity decreased. Sway density curve analysis indicated that balance motor commands in AIS patients were much more variable than in the controls: their mean peak increased slightly across time; therefore, the CP of AIS patients did not spend much time within the stability area compared to the controls (Fig. 2, lower panel).

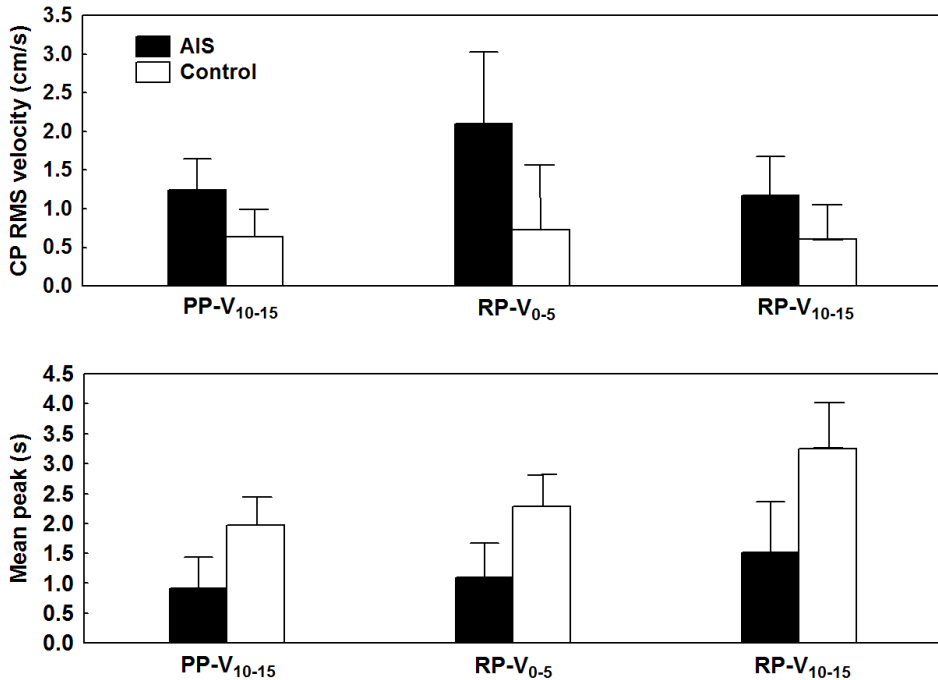


Fig. 2. Balance control performance during reintegration of ankle proprioception when vision is available. The upper panel illustrates Group by Epoch interaction for CP RMS velocity for the last 5-s epoch of the sensory deprivation interval (PP-V₁₀₋₁₅ perturbed proprioception/vision) and for the first and last 5-s epoch of the sensory reintegration interval (RP-V₀₋₅ and RP-V₁₀₋₁₅ reintegration proprioception/vision). The lower panel shows Group by Epoch interaction for time spent within the zone of stability for the same 5-s epochs as in the upper panels. In all panels, the error bars correspond to 95% confidence intervals. Cited from Simoneau et al. 2006a BMC Neuroscience under Creative Commons licence.

A significant group difference was also demonstrated when participants had to reintegrate ankle proprioception in the absence of vision. For instance, balance stability analysis after the reintegration of proprioception without vision indicated that AIS patients' CP RMS velocity was larger than that of the controls and differed across time (Fig. 3, upper panel). Moreover, the sway density curve (Fig. 3, lower panel) disclosed that balance control commands in AIS patients were more variable than in the controls during the first 5 s of the sensory reintegration interval (RP-NV₀₋₅) as their mean peak did not increase from PP-NV₁₀₋₁₅ to RP-NV₀₋₅ ($p > 0.05$). In contrast, control participants reduced the variability of their balance control commands as their mean peak increased from PP-NV₁₀₋₁₅ to RP-NV₀₋₅ ($p < 0.01$).

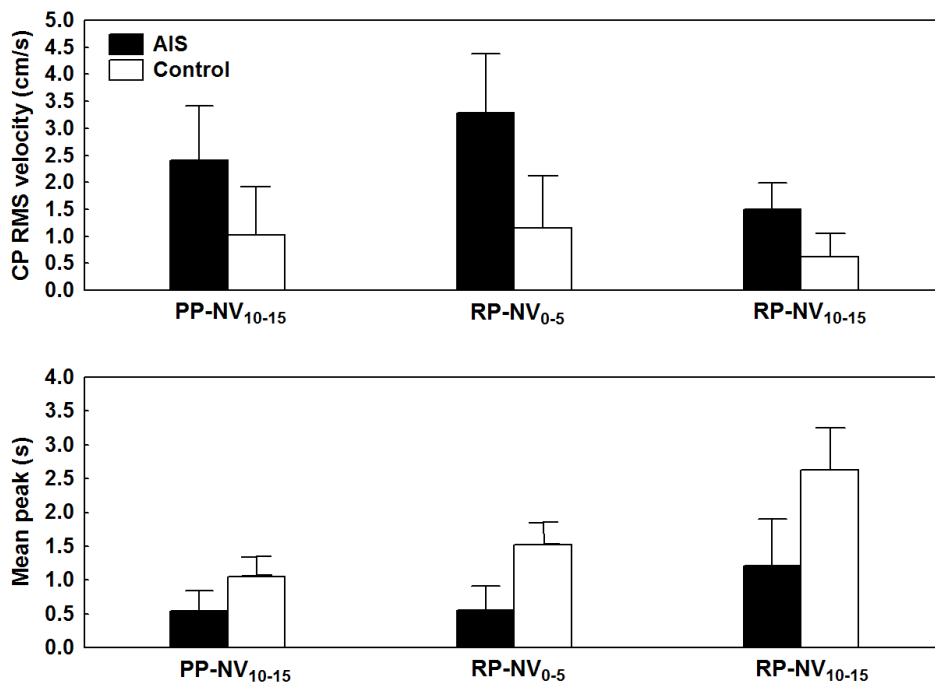


Fig. 3. Balance control performance during reintegration of ankle proprioception in the absence of vision. The upper panel presents Group by Epoch interaction for CP RMS velocity for the last 5-s epoch of the sensory deprivation interval (PP-NV₁₀₋₁₅ perturbed proprioception/no-vision) and for the first and last 5-s epoch of the sensory reintegration interval (RP-NV₀₋₅ and RP-NV₁₀₋₁₅ reintegration proprioception/no-vision condition). The lower panel illustrates Group by Epoch interaction for time spent within the zone of stability for the same 5-s epochs as in the upper panels. In all panels, the error bars indicate 95% confidence intervals. Cited from Simoneau et al. 2006a BMC Neuroscience under Creative Commons licence.

The originality of our results is that AIS patients showed greater CP RMS velocity after the reintegration of proprioception information from muscles acting at the ankle joint. This was observed whether or not vision was available. In contrast, the controls were able to maintain or rapidly reduce their CP RMS velocity when proprioceptive information from the lower leg muscles returned to normal. Furthermore, in the absence of vision, AIS patients exhibited increased CP RMS velocity after the reintegration of ankle proprioception. The increase in CP RMS velocity observed in the context of sensory transition (i.e., sensory information returned to normal; no tendon vibration and/or eyes open) indicates that the central sensory reweighing mechanisms are less effective in AIS patients. Moreover, the greater CP RMS velocity noted during sensory reintegration suggests that AIS patients' balance control commands were inappropriate. Analysis of their sway density plots

confirmed that AIS patients had greater mean peak (balance control command variability) and mean distance (balance control command amplitude). This could result from improper transformation of sensory orientation cues into corrective balance control commands.

4. The vestibular system

Although the etiopathology of scoliosis is not well understood (Jensen & Wilson, 1979; Manzoni & Miele, 2002), we believe that impaired responses of the vestibulo-spinal tracts could contribute to spine curvature and its progression. This hypothesis derives from clinical and animal studies which demonstrated that stimulation of vestibular nuclei (vestibulo-spinal tract) activated the back muscles (Ali et al., 2003; Ardic et al., 2000; Britton et al., 1993; Schwartz-Giblin et al., 1984a; Schwartz-Giblin et al., 1984b; Siegel & Tomaszewski, 1983). In addition, oculo-motor and postural vestibular deficits have been reported to range from 50 to 85% in AIS, whereas these deficits represent 12 and 17% in the controls (Manzoni & Miele, 2002). It has been shown that some AIS patients have a lower gain of vestibulo-ocular reflexes (VOR) and a larger phase lead compared to age-matched controls. Moreover, AIS patients have a reduced duration of post-rotatory vestibular and optokinetic nystagmus as well as self-motion perception, with a significant relationship between the time constant of vestibular-elicited nystagmus and magnitude of the curvature; the shorter the time constant, the larger the curvature (Manzoni & Miele, 2002). Moreover, these authors have reported that AIS patients with abnormal VOR showed a more progressive curve during growth. Finally, weaker predominance of the right vestibular apparatus is sometimes reported in AIS patients (Manzoni & Miele, 2002).

Various procedures – calorimetric test, vestibular-evoked myogenic potential (VEMP), vestibular chair and galvanic vestibular stimulation (GVS) – can evaluate vestibular system integrity (Schubert & Minor, 2004). The calorimetric test is a gold standard for the identification of peripheral unilateral vestibular hypofunction by simply introducing warm or cold water in the external auditory canal. Unfortunately, this technique only stimulates the lateral semicircular canal and to a lesser extent than a physiological stimulus (Schubert & Minor, 2004). In contrast, VEMP stimulates only the otoliths and detects unilateral hypofunction with clicking sounds and by recording associated sternocleidomastoid muscle myogenic potentials (Schubert & Minor, 2004). The vestibular chair provides a physiological stimulus by rotating the seated patient around a vertical axis through the vertex. It explores both sides of the semicircular canals, VOR and vestibular integration (Blouin et al., 1997; Schubert & Minor, 2004). On the other hand, GVS is a procedure that can explore the semicircular canals and otoliths (Cathers et al., 2005). GVS generates ML body sway responses (Day et al., 1997; Fitzpatrick & Day, 2004) and AP body sway responses (Scinicariello et al., 2002; Severac Cauquil et al., 1998). It can create eye movements when high stimulation is delivered (Aw et al., 2006; Kim et al., 2006). GVS is an attractive tool because it probes vestibular function and reveals balance control system operation in response to pure vestibular perturbation, at least immediately after GVS onset. The direction of body sway responses after GVS varies with head orientation (Fitzpatrick & Day, 2004). Moreover, electrode positioning also influences the direction of the postural response. Different GVS configurations exist. For example, during bilateral bipolar stimulation, the most common configuration, an anodal electrode is located on the mastoid process behind one ear with the cathodal electrode behind the other ear. On the other hand, during bilateral monopolar GVS, both electrodes have the same polarity, and a reference electrode is located

on the forehead, for example. Because GVS produces a signal of head movement, the direction of the postural response depends upon head orientation, During monopolar GVS, body sway will be along the AP axis whereas it will be along the ML axis during bilateral bipolar stimulation (Fitzpatrick & Day, 2004).

4.1 Cognitive exploration and the vestibular chair

Although various studies have proven that some AIS patients have abnormal VOR (Manzoni & Miele, 2002), little attention has been devoted to assessing the capacity of AIS patients to integrate vestibular information for cognitive processing of space perception. Consequently, we investigated the ability of AIS patients to process vestibular information for space updating (Simoneau et al., 2009). In this experiment, seated AIS patients and controls experienced torso rotations of different directions and amplitudes in the dark and produced saccades that would reproduce their perceived spatial characteristic of the rotations (vestibular condition). Furthermore, we controlled for possible alteration of the oculomotor and vestibular systems by measuring subject accuracy in performing saccades toward memorized peripheral targets in the absence of body rotation and gain of their vestibulo-ocular reflex. Ten IS patients (9 females, mean age: 17.4 years, Cobb's angle: 28-51) and 13 age-matched healthy individuals (11 females, mean age: 16.4 years) were tested. The participants sat on a chair in a completely dark room and were able to rotate around its central vertical axis, located in the center of a black cylinder with a radius of 1.5 m. The pseudo-randomly selected magnitudes of whole-body rotation were 10°, 20° or 30°. Whole-body rotation was clockwise for half of the trials and counter-clockwise for the other half. Horizontal eye movements were recorded by electro-oculography.

The experimental session consisted of a main experimental condition that tested the ability of participants to process vestibular inputs (i.e., cognitive vestibular condition) and 2 control conditions, one that examined the subjects' capacity to produce accurate saccadic eye movements (i.e., visual condition) and the other that controlled for possible alteration of the vestibular system (i.e., vestibulo-ocular reflex condition). The participants were passively rotated in the cognitive vestibular condition. Eye movements were attenuated during body rotations by asking them to look at a chair-fixed diode positioned straight ahead. After rotation, they produced a saccade to shift their gaze to their initial position (Fig. 4: "vestibular memory-contingent saccade" paradigm (Bloomberg et al., 1988)). Saccade amplitude (i.e., perceived body rotation amplitude) was measured at the end of the first saccade (defined as the first instant that eye velocity dropped below 5°/s after saccade onset). Therefore, participants had to process and memorize the vestibular signals generated during whole-body rotation to produce a saccade of equal magnitude but in the opposite direction of the rotations.

Cognitive vestibular gain analysis (Fig. 5) showed that both groups underestimated whole-body rotation, as demonstrated by their average ratios which were inferior to 1. Nonetheless, AIS patients underestimated the magnitude of whole-body rotation to a greater extent than control participants (mean of 0.65 and 0.82 for the AIS and control groups, respectively; main Group effect: $F_{1,20}=5.57$, $p<0.05$). For both groups, the directions of chair rotation and their amplitude had no effect on cognitive vestibular gains.

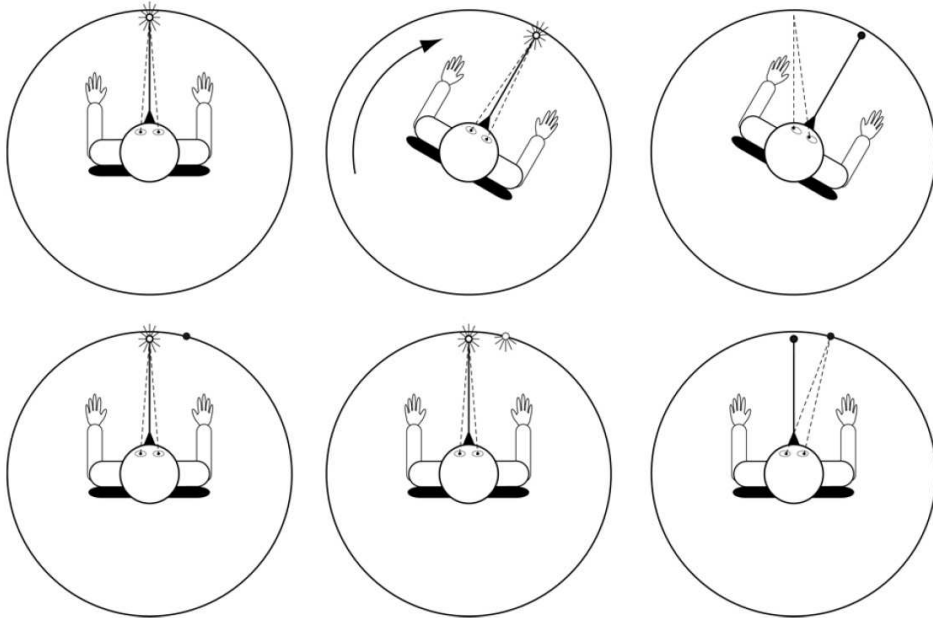


Fig. 4. Schema of the experimental set-up: the upper panels depict the vestibular condition, and the lower panels, the visual condition. Participants looked at a chair-fixed light (CFL) before being submitted to whole-body rotation (upper left panel). Then, whole-body rotation mainly stimulated the horizontal semicircular canals (upper middle panel). After rotation, the CFL was turned off and the participants performed a saccade to the starting position (upper right panel). In the visual condition, participants looked at the CFL (lower left panel). Then, the peripheral target lit up for 0.2 s (lower middle panel). Finally, after 1 s, the CFL was turned off and the participants performed a saccade to the peripheral target (lower right panel). Cited from Simoneau et al. 2009 BMC Neuroscience under Creative Commons licence.

Saccades in the absence of whole-body rotation were accurate, with no significant difference in amplitude between groups ($t=1.88$, $df=20$, $p>0.05$). Furthermore, analysis revealed that the VOR gain of AIS patients did not differ from that of control participants, regardless of rotation direction (no main Group or Direction effect and no Group by Direction interaction: $p>0.05$). The performance of accurate saccades by AIS patients to memorize the targets excluded any saccadic motor deficit. This observation substantiates previous results suggesting that the network assisting the control of vestibular memory-guided saccades is different from the one governing visual memory-guided saccades (Israel et al., 1995; Pierrot-Deseilligny et al., 1991). Moreover, the fact that AIS patients had normal VOR gains confirms that the vestibular system in these patients is normal. Overall, this study revealed that, compared to the controls, AIS patients underestimated the amplitude of rotations, indicating impairment of their ability to memorize and process vestibular signals. It is possible that severe spinal deformity was partly due to impaired vestibular information travelling from the cerebellum to the vestibular cortical network or alteration in the cortical

mechanisms processing vestibular signals. However, these results do not allow us to make claims as to whether deficits in the cognitive processing of vestibular signals should be considered as a potential factor leading to curvature progression in scoliosis patients. Further studies may determine if this deficit and melatonin signalling dysfunction in AIS can predict curve progression in patients with small spinal deformity.

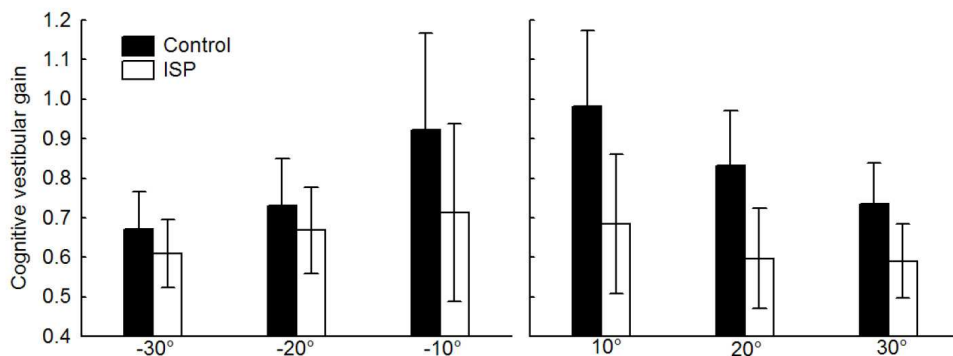


Fig. 5. Vestibular cognitive gain with chair rotations of 10, 20 and 30° in both directions (error bars represent $\pm 95\%$ confidence intervals). Cited from Simoneau et al. 2009 BMC Neuroscience under Creative Commons licence.

4.2 Integration and motor responses

Vestibular information is also used to maintain posture and balance. To this end, vestibulo-motor responses during head movements are sent to the postural muscles through the vestibulo-spinal and reticulo-spinal tracts.

4.2.1 GVS

GVS serves to manipulate vestibular sensory information (i.e., semicircular canals and otoliths) and to evoke vestibulo-motor responses. Binaural bipolar GVS stimulation is known to provoke body sway towards the anode side (Ardic et al., 2000; Marsden et al., 2003; Marsden et al., 2002).

4.2.2 Do AIS patients have abnormal vestibulo-motor responses?

After the literature review presented above concerning the possible implication of sensorimotor impairments in IS, we hypothesized that AIS patients will show vestibulo-motor responses along the frontal plane that differ from control values. If this hypothesis is confirmed, during and after GVS, the amplitude of postural responses of AIS patients should be different from that of the controls.

We, therefore, conducted a pilot study to verify the hypothesis. Eight AIS patients [mean Cobb's angle: 40.5° ($\pm 5.9^\circ$), mean age: 15.5 (± 1.4) years, mean height: 165.5 (± 9.0) cm, mean weight: 59.3 (± 14.5) kg] and 8 control participants [mean age: 12.4 (± 2.0) years, mean height: 158.3 (± 7.1) cm, mean weight: 49.7 (± 7.7) kg] were tested. Both groups underwent 15 trials

that lasted 8 s. Participants had their eyes closed at all times. GVS was a step response that lasted 2 s and had an amplitude of 1 mA. GVS direction was randomized: left GVS (L-GVS) anode left and cathode right, and right GVS (R-GVS) anode right and cathode left.

To quantify lateral displacement of the body along the frontal plane, 3 electromagnetic sensors (Polhemus Liberty Model, sampling frequency 120 Hz) were located on the participants' forehead, 7th cervical vertebra and 1st lumbar vertebra. So far, qualitative analysis revealed that the kinematic responses of healthy controls are similar to those of adult individuals (Day et al., 1997; Marsden et al., 2003; Marsden et al., 2002; Marsden et al., 2005). For instance, the maximum displacement of each body part (i.e., head, upper and lower trunk) along the frontal plane is less than 1 cm and is reached during GVS (Fig. 6). It is noteworthy that control participants returned to their initial position approximately 1 s after the end of GVS.

In AIS patients, maximal lateral displacement along the frontal plane was approximately 2 times greater than in the controls (Fig. 7). Furthermore, after GVS, AIS patients required much more time to return to their initial position and some oscillations were even observed (Fig. 7).

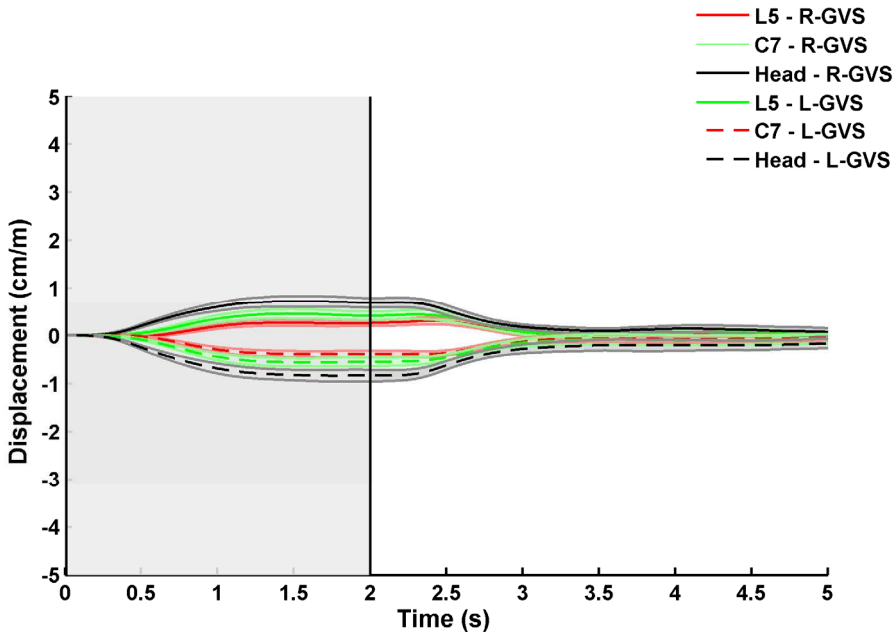


Fig. 6. Mean lateral displacement along the frontal plane for the control group (0 s corresponds to GVS onset, and the vertical line indicates when GVS stops). The solid lines are for right to left GVS (R-GVS), and the dashed lines are for left to right GVS (L-GVS). The shaded areas represent standard errors.

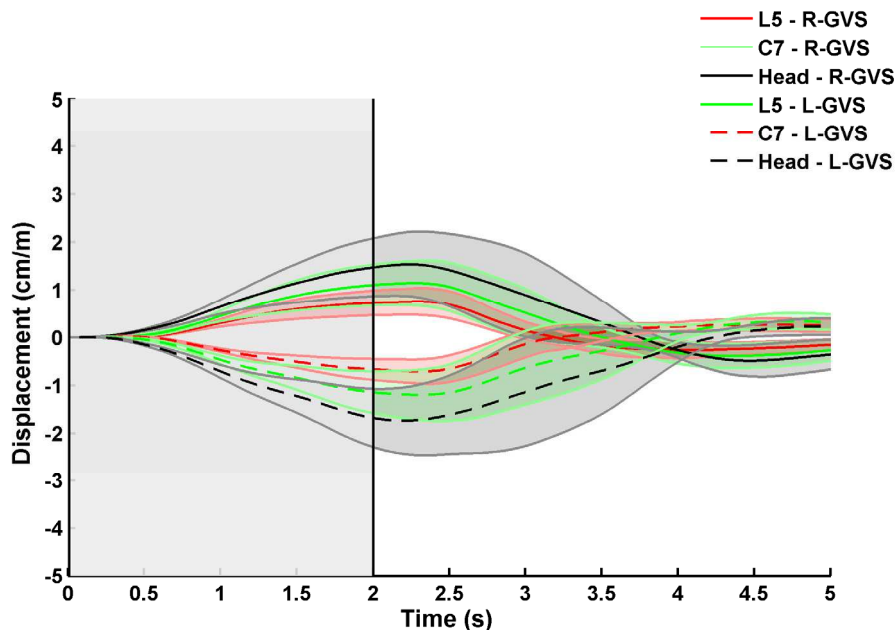


Fig. 7. Mean lateral displacement along the frontal plane for the AIS group (0 s corresponds to GVS onset, and the vertical line indicates when GVS stops). The solid lines are for right to left GVS (R-GVS), and the dashed lines are for left to right GVS (L-GVS). The shaded areas represent standard errors.

These results clearly show that stimulation of the vestibular apparatus in AIS patients evokes a larger kinematics response than in the controls. In addition, because AIS patients required more time than the controls to return to equilibrium after GVS cessation, this observation suggests that AIS patients have more difficulties in reweighting sensory information.

The results of this pilot study support our previous results. Using a different sensory channel (vestibular rather than vision and proprioception), we showed that the cortical mechanisms reweighting sensory information are altered in AIS patients (Simoneau et al., 2006a; Simoneau et al., 2006b).

5. Conclusion

Although the aetiology of IS remains unknown, a growing body of evidence indicates that spinal deformity could be the expression of a subclinical nervous system disorder. Consequently, impairment of sensorimotor transformation may lead to abnormal postural tone and may create spinal curvature during growth.

Future research should assess whether sensory integration and motor response impairments correlate with neuroanatomical changes in the CNS.

6. Acknowledgments

We would like to express our gratitude to all study subjects and their parents for their participation and patience. In addition, we thank *La Fondation Yves Cotrel – Institut de France*, *Fonds de la recherche en santé du Québec*, *Fondation de recherche en chiropratique du Québec* and *the Natural Sciences and Engineering Research Council of Canada* for financial support.

7. References

- Ali, A.S.; Rowen, K.A. & Iles, J.F. (2003). Vestibular actions on back and lower limb muscles during postural tasks in man. *The Journal of Physiology*, Vol. 546, No. Pt 2, (January 2003), pp. 615-624, ISSN 0022-3751.
- Ardic, F.N.; Latt, L.D. & Redfern, M.S. (2000). Paraspinal muscle response to electrical vestibular stimulation. *Acta Oto-Laryngologica*, Vol. 120, No. 1, (January 2000), pp. 39-46, ISSN 0001-6489.
- Aw, S.T.; Todd, M.J. & Halmagyi, G.M. (2006). Latency and initiation of the human vestibuloocular reflex to pulsed galvanic stimulation. *Journal of Neurophysiology*, Vol. 96, No. 2, (August 2006), pp. 925-930, ISSN 0022-3077.
- Baratto, L.; Morasso, P.G.; Re, C. & Spada, G. (2002). A new look at posturographic analysis in the clinical context: sway-density versus other parameterization techniques. *Motor Control*, Vol. 6, No. 3, (July 2002), pp. 246-270, ISSN 1087-1640.
- Barrack, R.L.; Wyatt, M.P.; Whitecloud, T.S., 3rd; Burke, S.W.; Roberts, J.M. & Brinker, M.R. (1988). Vibratory hypersensitivity in idiopathic scoliosis. *Journal of Pediatric Orthopedics*, Vol. 8, No. 4, (July-August 1988), pp. 389-395, ISSN 0271-6798.
- Barson, A.J. (1970). The vertebral level of termination of the spinal cord during normal and abnormal development. *Journal of Anatomy*, Vol. 106, No. Pt 3, (May 1970), pp. 489-497, ISSN 0021-8782.
- Beaulieu, M.; Toulotte, C.; Gatto, L.; Rivard, C.H.; Teasdale, N.; Simoneau, M. & Allard, P. (2009). Postural imbalance in non-treated adolescent idiopathic scoliosis at different periods of progression. *European Spine Journal*, Vol. 18, No. 1, (January 2009), pp. 38-44, ISSN 0940-6719.
- Benli, I.T.; Un, A.; Karaaslan, S.; Cinemre, O.; Gurses, L. & Hekimoglu, B. (2002). [Neural axis abnormalities detected by preoperative magnetic resonance imaging in patients with type III idiopathic scoliosis]. *Acta Orthop Traumatol Turc*, Vol. 36, No. 4, (January 2002), pp. 354-361, ISSN 1017-995X.
- Bloomberg, J.; Jones, G.M.; Segal, B.; McFarlane, S. & Soul, J. (1988). Vestibular-contingent voluntary saccades based on cognitive estimates of remembered vestibular information. *Advances in Oto-Rhino-Laryngology*, Vol. 41, (January 1988 1988), pp. 71-75, ISSN 0065-3071.
- Blouin, J.; Gauthier, G.M. & Vercher, J.L. (1997). Visual object localization through vestibular and neck inputs. 2: Updating off-mid-sagittal-plane target positions. *Journal of Vestibular Research*, Vol. 7, No. 2-3, (March-June 1997), pp. 137-143, ISSN 0957-4271.
- Brinker, M.R.; Willis, J.K.; Cook, S.D.; Whitecloud, T.S., 3rd; Bennett, J.T.; Barrack, R.L. & Ellman, M.G. (1992). Neurologic testing with somatosensory evoked potentials in idiopathic scoliosis. *Spine*, Vol. 17, No. 3, (March 1992), pp. 277-279, ISSN 0362-2436.
- Britton, T.C.; Day, B.L.; Brown, P.; Rothwell, J.C.; Thompson, P.D. & Marsden, C.D. (1993). Postural electromyographic responses in the arm and leg following galvanic


- vestibular stimulation in man. *Experimental Brain Research*, Vol. 94, No. 1, (January 1993), pp. 143-151, ISSN 0014-4819.
- Byl, N.N. & Gray, J.M. (1993). Complex balance reactions in different sensory conditions: adolescents with and without idiopathic scoliosis. *Journal of Orthopaedic Research*, Vol. 11, No. 2, (March 1993), pp. 215-227, ISSN 0736-0266.
- Byl, N.N.; Holland, S.; Jurek, A. & Hu, S.S. (1997). Postural imbalance and vibratory sensitivity in patients with idiopathic scoliosis: implications for treatment. *Journal of Orthopaedic and Sports Physical Therapy*, Vol. 26, No. 2, (August 1997), pp. 60-68, ISSN 0190-6011.
- Cathers, I.; Day, B.L. & Fitzpatrick, R.C. (2005). Otolith and canal reflexes in human standing. *The Journal of Physiology*, Vol. 563, No. Pt 1, (February 2005), pp. 229-234, ISSN 0022-3751.
- Cheng, J.C.; Chau, W.W.; Guo, X. & Chan, Y.L. (2003). Redefining the magnetic resonance imaging reference level for the cerebellar tonsil: a study of 170 adolescents with normal versus idiopathic scoliosis. *Spine*, Vol. 28, No. 8, (April 2003), pp. 815-818, ISSN 0362-2436.
- Cheng, J.C.; Guo, X. & Sher, A.H. (1998). Posterior tibial nerve somatosensory cortical evoked potentials in adolescent idiopathic scoliosis. *Spine*, Vol. 23, No. 3, (February 1998), pp. 332-337, ISSN 0362-2436.
- Cheng, J.C.; Guo, X.; Sher, A.H.; Chan, Y.L. & Metreweli, C. (1999). Correlation between curve severity, somatosensory evoked potentials, and magnetic resonance imaging in adolescent idiopathic scoliosis. *Spine*, Vol. 24, No. 16, (August 1999), pp. 1679-1684, ISSN 0362-2436.
- Chu, W.C.; Lam, W.W.; Chan, Y.L.; Ng, B.K.; Lam, T.P.; Lee, K.M.; Guo, X. & Cheng, J.C. (2006). Relative shortening and functional tethering of spinal cord in adolescent idiopathic scoliosis?: study with multiplanar reformat magnetic resonance imaging and somatosensory evoked potential. *Spine*, Vol. 31, No. 1, (January 2006), pp. E19-E25, ISSN 0362-2436.
- Chu, W.C.; Man, G.C.; Lam, W.W.; Yeung, B.H.; Chau, W.W.; Ng, B.K.; Lam, T.P.; Lee, K.M. & Cheng, J.C. (2007). A detailed morphologic and functional magnetic resonance imaging study of the craniocervical junction in adolescent idiopathic scoliosis. *Spine*, Vol. 32, No. 15, (July 2007), pp. 1667-1674, ISSN 0362-2436.
- Chu, W.C.; Man, G.C.; Lam, W.W.; Yeung, B.H.; Chau, W.W.; Ng, B.K.; Lam, T.P.; Lee, K.M. & Cheng, J.C. (2008). Morphological and functional electrophysiological evidence of relative spinal cord tethering in adolescent idiopathic scoliosis. *Spine*, Vol. 33, No. 6, (March 2008), pp. 673-680, ISSN 0362-2436.
- Colombo, L.F. & Motta, F. (2011). Consensus conference on Chiari: a malformation or an anomaly? Scoliosis and others orthopaedic deformities related to Chiari 1 malformation. *Neurological Sciences*, Vol. 32, No. Suppl. 3 (September 2011), ISSN 1590-1874.
- Day, B.L.; Severac Cauquil, A.; Bartolomei, L.; Pastor, M.A. & Lyon, I.N. (1997). Human body-segment tilts induced by galvanic stimulation: a vestibularly driven balance protection mechanism. *The Journal of Physiology*, Vol. 500, No. Pt 3, (May 1997), pp. 661-672, ISSN 0022-3751.
- Do, T.; Fras, C.; Burke, S.; Widmann, R.F.; Rawlins, B. & Boachie-Adjei, O. (2001). Clinical value of routine preoperative magnetic resonance imaging in adolescent idiopathic

- scoliosis. A prospective study of three hundred and twenty-seven patients. *Journal of Bone and Joint Surgery*, Vol. 83-A, No. 4, (April 2001), pp. 577-579, ISSN 0021-9355.
- Domenech, J.; Tormos, J.M.; Barrios, C. & Pascual-Leone, A. (2010). Motor cortical hyperexcitability in idiopathic scoliosis: could focal dystonia be a subclinical etiological factor? *European Spine Journal*, Vol. 19, No. 2, (February 2010), pp. 223-230, ISSN 0940-6719.
- Fernandez-Bermejo, E.; Garcia-Jimenez, M.A.; Fernandez-Palomeque, C. & Munuera, L. (1993). Adolescent idiopathic scoliosis and joint laxity. A study with somatosensory evoked potentials. *Spine*, Vol. 18, No. 7, (June 1993), pp. 918-922, ISSN 0362-2436.
- Fitzpatrick, R.C. & Day, B.L. (2004). Probing the human vestibular system with galvanic stimulation. *Journal of Applied Physiology*, Vol. 96, No. 6, (June 2004), pp. 2301-2316, ISSN 0161-7567.
- Geissele, A.E.; Kransdorf, M.J.; Geyer, C.A.; Jelinek, J.S. & Van Dam, B.E. (1991). Magnetic resonance imaging of the brain stem in adolescent idiopathic scoliosis. *Spine*, Vol. 16, No. 7, (July 1991), pp. 761-763, ISSN 0362-2436.
- Guo, X.; Chau, W.W.; Hui-Chan, C.W.; Cheung, C.S.; Tsang, W.W. & Cheng, J.C. (2006). Balance control in adolescents with idiopathic scoliosis and disturbed somatosensory function. *Spine*, Vol. 31, No. 14, (June 2006), pp. E437-E440, ISSN 0362-2436.
- Haumont, T.; Gauchard, G.C.; Lascombes, P. & Perrin, P.P. (2011). Postural instability in early-stage idiopathic scoliosis in adolescent girls. *Spine*, Vol. 36, No. 13, (February 2011), ISSN 0362-2436.
- Hausmann, O.N.; Boni, T.; Pfirrmann, C.W.; Curt, A. & Min, K. (2003). Preoperative radiological and electrophysiological evaluation in 100 adolescent idiopathic scoliosis patients. *European Spine Journal*, Vol. 12, No. 5, (October 2003), pp. 501-506, ISSN 0940-6719.
- Herman, R.; Mixon, J.; Fisher, A.; Maulucci, R. & Stuyck, J. (1985). Idiopathic scoliosis and the central nervous system: a motor control problem. The Harrington lecture, 1983. Scoliosis Research Society. *Spine*, Vol. 10, No. 1, (January-February 1985), pp. 1-14, ISSN 0362-2436.
- Inoue, M.; Minami, S.; Nakata, Y.; Otsuka, Y.; Takaso, M.; Kitahara, H.; Tokunaga, M.; Isobe, K. & Moriya, H. (2005). Preoperative MRI analysis of patients with idiopathic scoliosis: a prospective study. *Spine*, Vol. 30, No. 1, (January 2005), pp. 108-114, ISSN 0362-2436.
- Inoue, M.; Nakata, Y.; Minami, S.; Kitahara, H.; Otsuka, Y.; Isobe, K.; Takaso, M.; Tokunaga, M.; Itabashi, T.; Nishikawa, S. & Moriya, H. (2003). Idiopathic scoliosis as a presenting sign of familial neurologic abnormalities. *Spine*, Vol. 28, No. 1, (January 2003), pp. 40-45, ISSN 0362-2436.
- Israel, I.; Rivaud, S.; Gaymard, B.; Berthoz, A. & Pierrot-Deseilligny, C. (1995). Cortical control of vestibular-guided saccades in man. *Brain*, Vol. 118, No. Pt 5, (October 1995), pp. 1169-1183, ISSN 0006-8950.
- Jensen, G.M. & Wilson, K.B. (1979). Horizontal postrotatory nystagmus response in female subjects with adolescent idiopathic scoliosis. *Physical Therapy*, Vol. 59, No. 10, (October 1979), pp. 1226-1233, ISSN 0031-9023.

- Kim, H.J.; Choi, J.Y.; Son, E.J. & Lee, W.S. (2006). Response to galvanic vestibular stimulation in patients with unilateral vestibular loss. *Laryngoscope*, Vol. 116, No. 1, (January 2006), pp. 62-66, ISSN 0023-852X.
- Krieger, M.D.; Falkinstein, Y.; Bowen, I.E.; Tolo, V.T. & McComb, J.G. (2011). Scoliosis and Chiari malformation Type I in children. *Journal of Neurosurgery: Pediatrics*, Vol. 7, No. 1, (January 2011), pp. 25-29, ISSN 1933-0707.
- Lam, T.P.; Hung, V.W.; Yeung, H.Y.; Tse, Y.K.; Chu, W.C.; Ng, B.K.; Lee, K.M.; Qin, L. & Cheng, J.C. (2011). Abnormal bone quality in adolescent idiopathic scoliosis: a case-control study on 635 subjects and 269 normal controls with bone densitometry and quantitative ultrasound. *Spine*, Vol. 36, No. 15, (July 2011), pp. 1211-1217, ISSN 0362-2436.
- Lao, M.L.; Chow, D.H.; Guo, X.; Cheng, J.C. & Holmes, A.D. (2008). Impaired dynamic balance control in adolescents with idiopathic scoliosis and abnormal somatosensory evoked potentials. *Journal of Pediatric Orthopedics*, Vol. 28, No. 8, (December 2008), pp. 846-849, ISSN 1539-2570.
- Liszka, O. (1961). Spinal cord mechanisms leading to scoliosis in animal experiments. *Acta Medica Polona*, Vol. 2, (January 1961), pp. 45-63, ISSN 0001-608X.
- Little, D.G.; Song, K.M.; Katz, D. & Herring, J.A. (2000). Relationship of peak height velocity to other maturity indicators in idiopathic scoliosis in girls. *Journal of Bone and Joint Surgery*, Vol. 82, No. 5, (May 2000), pp. 685-693, ISSN 0021-9355.
- Machida, M.; Dubousset, J.; Imamura, Y.; Iwaya, T.; Yamada, T.; Kimura, J. & Toriyama, S. (1994). Pathogenesis of idiopathic scoliosis: SEPs in chicken with experimentally induced scoliosis and in patients with idiopathic scoliosis. *Journal of Pediatric Orthopedics*, Vol. 14, No. 3, (May-June 1994), pp. 329-335, ISSN 0271-6798.
- Maguire, J.; Madigan, R.; Wallace, S.; Leppanen, R. & Draper, V. (1993). Intraoperative long-latency reflex activity in idiopathic scoliosis demonstrates abnormal central processing. A possible cause of idiopathic scoliosis. *Spine*, Vol. 18, No. 12, (September 1993), pp. 1621-1626, ISSN 0362-2436.
- Maiocco, B.; Deeney, V.F.; Coulon, R. & Parks, P.F., Jr. (1997). Adolescent idiopathic scoliosis and the presence of spinal cord abnormalities. Preoperative magnetic resonance imaging analysis. *Spine*, Vol. 22, No. 21, (November 1997), pp. 2537-2541, ISSN 0362-2436.
- Manzoni, D. & Miele, F. (2002). Vestibular mechanisms involved in idiopathic scoliosis. *Archives Italiennes de Biologie*, Vol. 140, No. 1, (January 2002), pp. 67-80, ISSN 0003-9829.
- Marsden, J.F.; Blakey, G. & Day, B.L. (2003). Modulation of human vestibular-evoked postural responses by alterations in load. *The Journal of Physiology*, Vol. 548, No. Pt 3, (May 2003), pp. 949-953, ISSN 0022-3751.
- Marsden, J.F.; Castellote, J. & Day, B.L. (2002). Bipedal distribution of human vestibular-evoked postural responses during asymmetrical standing. *The Journal of Physiology*, Vol. 542, No. Pt 1, (July 2002), pp. 323-331, ISSN 0022-3751.
- Marsden, J.F.; Playford, D.E. & Day, B.L. (2005). The vestibular control of balance after stroke. *Journal of Neurology, Neurosurgery and Psychiatry*, Vol. 76, No. 5, (May 2005), pp. 670-678, ISSN 0022-3050.

- McInnes, E.; Hill, D.L.; Raso, V.J.; Chetner, B.; Greenhill, B.J. & Moreau, M.J. (1991). Vibratory response in adolescents who have idiopathic scoliosis. *Journal of Bone and Joint Surgery*, Vol. 73, No. 8, (September 1991), pp. 1208-1212, ISSN 0021-9355.
- Olafsson, Y.; Odergren, T.; Persson, H.E. & Saraste, H. (2002). Somatosensory testing in idiopathic scoliosis. *Developmental Medicine and Child Neurology*, Vol. 44, No. 2, (February 2002), pp. 130-132, ISSN 0012-1622.
- Pierrot-Deseilligny, C.; Rivaud, S.; Gaymard, B. & Agid, Y. (1991). Cortical control of memory-guided saccades in man. *Experimental Brain Research*, Vol. 83, No. 3, (1991), pp. 607-617, ISSN 0014-4819.
- Pincott, J.R.; Davies, J.S. & Taffs, L.F. (1984). Scoliosis caused by section of dorsal spinal nerve roots. *Journal of Bone and Joint Surgery. British Volume*, Vol. 66, No. 1, (January 1984), pp. 27-29, ISSN 0301-620X.
- Pincott, J.R. & Taffs, L.F. (1982). Experimental scoliosis in primates: a neurological cause. *Journal of Bone and Joint Surgery. British Volume*, Vol. 64, No. 4, (January 1982), pp. 503-507, ISSN 0301-620X.
- Rajasekaran, S.; Kamath, V.; Kiran, R. & Shetty, A.P. (2010). Intraspinal anomalies in scoliosis: An MRI analysis of 177 consecutive scoliosis patients. *Indian Journal of Orthopaedics*, Vol. 44, No. 1, (January 2010), pp. 57-63, ISSN 0019-5413.
- Rousie, D.; Hache, J.C.; Pellerin, P.; Deroubaix, J.P.; Van Tichelen, P. & Berthoz, A. (1999). Oculomotor, postural, and perceptual asymmetries associated with a common cause. Craniofacial asymmetries and asymmetries in vestibular organ anatomy. *Annals of the New York Academy of Sciences*, Vol. 871, (May 1999), pp. 439-446, ISSN 0077-8923.
- Sahlstrand, T.; Ortengren, R. & Nachemson, A. (1978). Postural equilibrium in adolescent idiopathic scoliosis. *Acta Orthopaedica Scandinavica*, Vol. 49, No. 4, (August 1978), pp. 354-365, ISSN 0001-6470.
- Schubert, M.C. & Minor, L.B. (2004). Vestibulo-ocular physiology underlying vestibular hypofunction. *Physical Therapy*, Vol. 84, No. 4, (April 2004), pp. 373-385, ISSN 0031-9023
- Schwartz-Giblin, S.; Femano, P.A. & Pfaff, D.W. (1984a). Axial electromyogram and intervertebral length gauge responses during lordosis behavior in rats. *Experimental Neurology*, Vol. 85, No. 2, (August 1984a), pp. 297-315, ISSN 0014-4886.
- Schwartz-Giblin, S.; Halpern, M. & Pfaff, D.W. (1984b). Segmental organization of rat lateral longissimus, a muscle involved in lordosis behavior: EMG and muscle nerve recordings. *Brain Research*, Vol. 299, No. 2, (May 1984b), pp. 247-257, ISSN 0006-8993.
- Scinicariello, A.P.; Inglis, J.T. & Collins, J.J. (2002). The effects of stochastic monopolar galvanic vestibular stimulation on human postural sway. *Journal of Vestibular Research*, Vol. 12, No. 2-3, (July 2002), pp. 77-85, ISSN 0957-4271.
- Severac Cauquil, A.; Gervet, M.F. & Ouaknine, M. (1998). Body response to binaural monopolar galvanic vestibular stimulation in humans. *Neuroscience Letters*, Vol. 245, No. 1, (March 1998), pp. 37-40, ISSN 0304-3940.
- Shen, W.J.; McDowell, G.S.; Burke, S.W.; Levine, D.B. & Chutorian, A.M. (1996). Routine preoperative MRI and SEP studies in adolescent idiopathic scoliosis. *Journal of Pediatric Orthopedics*, Vol. 16, No. 3, (May-June 1996), pp. 350-353, ISSN 0271-6798.

- Shi, L.; Wang, D.; Chu, W.C.; Burwell, G.R.; Wong, T.T.; Heng, P.A. & Cheng, J.C. (2011). Automatic MRI segmentation and morphoanatomy analysis of the vestibular system in adolescent idiopathic scoliosis. *Neuroimage*, Vol. 54, No. Suppl. 1 (January 2011), pp. S180-188, ISSN 1053-8119.
- Shi, L.; Wang, D.; Chu, W.C.; Burwell, R.G.; Freeman, B.J.; Heng, P.A. & Cheng, J.C. (2009). Volume-based morphometry of brain MR images in adolescent idiopathic scoliosis and healthy control subjects. *AJNR. American Journal of Neuroradiology*, Vol. 30, No. 7, (August 2009), pp. 1302-1307, ISSN 0195-6108.
- Siegel, J.M. & Tomaszewski, K.S. (1983). Behavioral organization of reticular formation: studies in the unrestrained cat. I. Cells related to axial, limb, eye, and other movements. *Journal of Neurophysiology*, Vol. 50, No. 3, (September 1983), pp. 696-716, ISSN 0022-3077.
- Simoneau, M.; Lamothe, V.; Hutin, E.; Mercier, P.; Teasdale, N. & Blouin, J. (2009). Evidence for cognitive vestibular integration impairment in idiopathic scoliosis patients. *BMC Neuroscience*, Vol. 10, No. (August 2009), p. 102, ISSN 1471-2202.
- Simoneau, M.; Mercier, P.; Blouin, J.; Allard, P. & Teasdale, N. (2006a). Altered sensory-weighting mechanisms is observed in adolescents with idiopathic scoliosis. *BMC Neuroscience*, Vol. 7, No. (October 2006), p. 68, ISSN 1471-2202.
- Simoneau, M.; Richer, N.; Mercier, P.; Allard, P. & Teasdale, N. (2006b). Sensory deprivation and balance control in idiopathic scoliosis adolescent. *Experimental Brain Research*, Vol. 170, No. 4, (April 2006), pp. 576-582, ISSN 0014-4819.
- Sun, X.; Qiu, Y.; Zhu, Z.; Zhu, F.; Wang, B.; Yu, Y. & Qian, B. (2007). Variations of the position of the cerebellar tonsil in idiopathic scoliotic adolescents with a Cobb angle >40 degrees: a magnetic resonance imaging study. *Spine*, Vol. 32, No. 15, (July 2007), pp. 1680-1686, ISSN 0362-2436.
- Wang, D.; Shi, L.; Chu, W.C.; Burwell, R.G.; Cheng, J.C. & Ahuja, A.T. (2012). Abnormal cerebral cortical thinning pattern in adolescent girls with idiopathic scoliosis. *Neuroimage*, Vol. 59, No. 2 (January 2012), ISSN 1053-8119.
- Winter, R.B.; Lonstein, J.E.; Heithoff, K.B. & Kirkham, J.A. (1997). Magnetic resonance imaging evaluation of the adolescent patient with idiopathic scoliosis before spinal instrumentation and fusion. A prospective, double-blinded study of 140 patients. *Spine*, Vol. 22, No. 8, (April 1997), pp. 855-858, ISSN 0362-2436.
- Wyatt, M.P.; Barrack, R.L.; Mubarak, S.J.; Whitecloud, T.S. & Burke, S.W. (1986). Vibratory response in idiopathic scoliosis. *Journal of Bone and Joint Surgery. British Volume*, Vol. 68, No. 5, (November 1986), pp. 714-718, ISSN 0301-620X.



Recent Advances in Scoliosis

Edited by Dr Theodoros Grivas

ISBN 978-953-51-0595-4

Hard cover, 344 pages

Publisher InTech

Published online 09, May, 2012

Published in print edition May, 2012

This book contains information on recent advances in aetiology and pathogenesis of idiopathic scoliosis, for the assessment of this condition before treatment and during the follow-up, making a note of emerging technology and analytical techniques like virtual anatomy by 3-D MRI/CT, quantitative MRI and Moire Topography. Some new trends in conservative treatment and the long term outcome and complications of surgical treatment are described. Issues like health related quality of life, psychological aspects of scoliosis treatment and the very important "patient's perspective" are also discussed. Finally two chapters tapping the untreated early onset scoliosis and the congenital kyphoscoliosis due to hemivertebra are included. It must be emphasized that knowledgeable authors with their contributions share their experience and enthusiasm with peers interested in scoliosis.

How to reference

In order to correctly reference this scholarly work, feel free to copy and paste the following:

Jean-Philippe Pialasse, Martin Descarreaux, Pierre Mercier, Jean Blouin and Martin Simoneau (2012). Sensorimotor Integration in Adolescent Idiopathic Scoliosis Patients, *Recent Advances in Scoliosis*, Dr Theodoros Grivas (Ed.), ISBN: 978-953-51-0595-4, InTech, Available from: <http://www.intechopen.com/books/recent-advances-in-scoliosis/sensorimotor-integration-in-adolescent-idiopathic-scoliosis-patients>

INTECH
open science | open minds

InTech Europe

University Campus STeP Ri
Slavka Krautzeka 83/A
51000 Rijeka, Croatia
Phone: +385 (51) 770 447
Fax: +385 (51) 686 166
www.intechopen.com

InTech China

Unit 405, Office Block, Hotel Equatorial Shanghai
No.65, Yan An Road (West), Shanghai, 200040, China
中国上海市延安西路65号上海国际贵都大饭店办公楼405单元
Phone: +86-21-62489820
Fax: +86-21-62489821